



## **NAAHTWG Slide of the Quarter (October – December 2005) - Infectious Pancreatic Necrosis (IPN) Virus (family Birnaviridae) in Atlantic salmon (*Salmo salar*)**

Case submitted by Dr Ken McColl, CSIRO -AAHL Fish Diseases Laboratory

### **Case History**

30 to 90 per cent mortality in two to three-month-old Atlantic *salmon* (*Salmo salar*) in a freshwater hatchery. Affected fish develop a dark body colour, and become slow and immobile, although small numbers show erratic swimming in a corkscrew manner.

### **Histopathology**

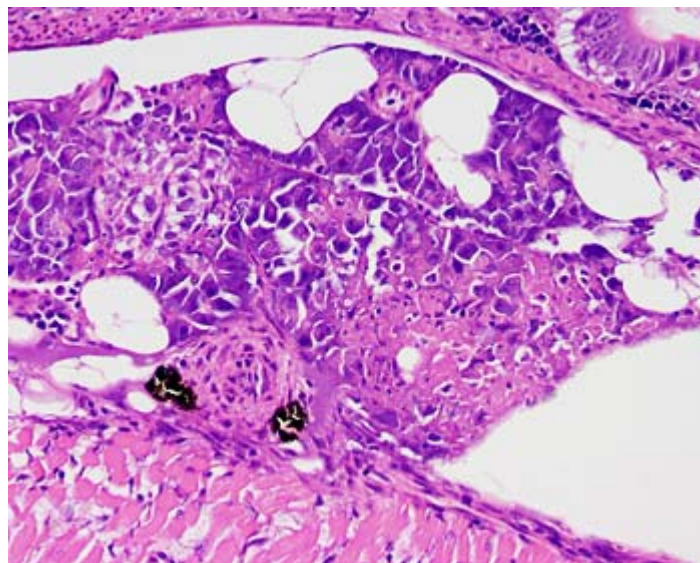
Pancreas: there is acute, multifocal and coalescing exocrine pancreatic necrosis. There is little evidence of inflammatory cell infiltration, although in some cases the lesions are oedematous with necrosis of adjacent adipose tissue.

### **Morphological Diagnosis**

Moderate to Severe, acute multifocal pancreatic necrosis.

### **Aetiological Diagnosis**

Infectious Pancreatic Necrosis (IPN) Virus (family Birnaviridae).  
Experimental case.



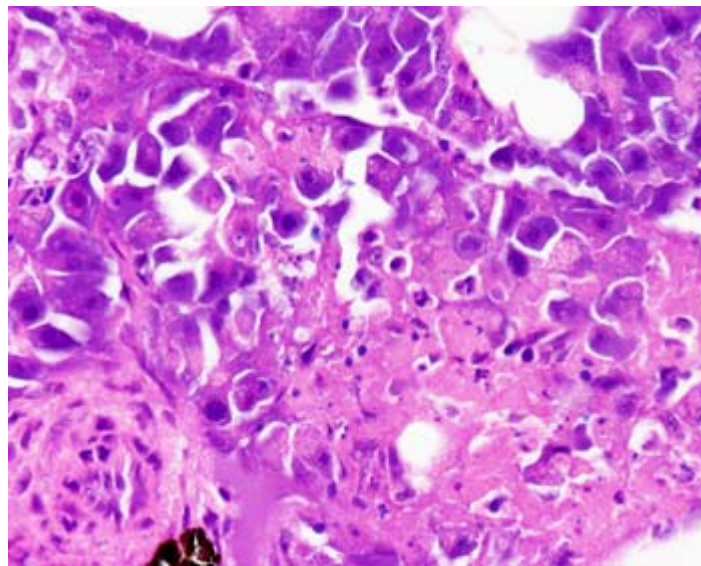


**Figure 1: low power H&E section showing focally extensive, acute coagulative necrosis of exocrine pancreatic tissue.**

### **Comment**

IPN is an exotic disease to Australia. While Australia does have its own birnavirus in fish (Tasmanian aquabirnavirus, TAB), the Australian virus has only been described in Macquarie Harbour in Tasmania, where it causes much lower mortality. Furthermore, TAB has never been found in freshwater hatcheries.

In young salmonids in freshwater hatcheries, the major lesions associated with IPN virus are usually restricted to the pancreas and intestinal tract (lesions in the adjacent adipose tissue may be due to release of pancreatic enzymes). In the increasingly important post-smolt syndrome (where IPN virus affects older fish in a marine environment), liver necrosis is also an important lesion.



**Figure 2: high power view of the same lesion as Figure 1, showing karyorrhectic nuclear material scattered throughout the featureless eosinophilic necrotic coagulum.**

### **Reference**

Crane M StJ, Hardy-Smith P, Williams LM, Hyatt AD, Eaton LM, Gould A, Handler J, Kattenbelt J and Gudkovs N. (2000) First isolation of an aquatic birnavirus from farmed and wild fish species in Australia. *Dis Aquat Org* 43:1-14

**NAAHTWG** - National Aquatic Animal Health Technical Working Group